



# In-flight syncope as the first manifestation of severe cardiodepressive vaso-vagal syndrome, verified by tilt-table testing with delayed response

Anna Wysocka<sup>1,A-D</sup>✉, Marcin Janowski<sup>2,A-B,E</sup>, Marcin Dzikusko<sup>2,B,E</sup>, Dominik Wyszyński<sup>2,B-C,E</sup>, Roman Śliwiak<sup>3,B,E</sup>, Andrzej Głowniak<sup>2,A,D-F</sup>

<sup>1</sup> Department of Internal Medicine and Internal Nursing, Faculty of Health Sciences, Medical University, Lublin, Poland

<sup>2</sup> Department of Cardiology, Medical University, Lublin, Poland

<sup>3</sup> Department of Cardiology, Specialist Hospital, Puławy, Poland

A – Research concept and design, B – Collection and/or assembly of data, C – Data analysis and interpretation, D – Writing the article, E – Critical revision of the article, F – Final approval of the article

Wysocka A, Janowski M, Dzikusko M, Wyszyński D, Śliwiak R, Głowniak A. In-flight syncope as the first manifestation of severe cardiodepressive vaso-vagal syndrome, verified by tilt-table testing with delayed response. *Ann Agric Environ Med*. doi: 10.26444/aaem/197756

## Abstract

A 66-year-old woman with a history of in-flight sedentary syncope, with normal results of ambulatory diagnostics, was referred to Clinical Electrophysiology Department for invasive electrophysiology study. The study revealed normal parameters, with no arrhythmia induced; a head-up tilt-test was performed, resulting in type I response with mild bradycardia and transient symptoms. After being released from the tilt-table, and while in the sitting position, she experienced full syncope with 20 s episode of complete A-V block recorded. The diagnosis was verified to type IIB syncope and the patient was implanted with dual-chamber pacemaker. Syncope is one of the most frequent medical in-flight emergencies; however, it is predominantly linked with disturbed autonomic system response to hypobaric hypoxia. During tilt-table testing, the described delayed cardiodepressive response was very unusual, it can still lead to accurate diagnosis and effective treatment, with no recurrent symptoms.

## Key words

in-flight syncope, vaso-vagal syndrome, tilt-test

## INTRODUCTION

Syncope is one of the most frequent medical in-flight emergencies, contributing to approximately one-in-four of all in-flight medical events and about 70% of flight diversions, with orthostatic hypotension and vaso-vagal syndrome (VVS) being the most common aetiology [1, 2].

VVS is a neurally mediated type of transient loss of consciousness that usually occurs in a standing position. Additional situational factors that typically trigger the reflex syncope are emotional stress, pain, or medical situations such as venipuncture. The loss of consciousness is usually preceded by such presyncopal symptoms as palpitations, excessive sweating, feeling of warmth, nausea, and turning pale. Syncope results from hypotension or/and relative bradycardia, followed by fatigue [3]. The tilt-table test (TTT) is an established tool for VVS diagnosis, performed using a Tilt-table in quiet, warm room, according several possible protocols/modifications. ECG of the patient is permanently monitored and blood pressure examined every 2 minutes. After 10 – 20 minutes in the supine position, the patient is tilted to 60° for the subsequent 20–45 minutes. Additional intervention in the form of nitroglycerine or isoprenaline administration or carotid sinus massage is possible for

suitable patients. The endpoints of TTT are, respectively, syncope occurrence or protocol completion. On the basis of TTT results, the following types of VVS may be diagnosed: 1) type 1 (mixed) when blood pressure falls before decrease in the heart rate, and the heart rate during syncope is not less than 40 beats per minute (bpm), or heart rate lower than 40 bpm lasts less than 10 seconds; 2) Type 2 (cardioinhibitory) with subtypes 2A (without asystole), when the heart rate decreases to less than 40 bpm for more than 10 seconds, but without asystole > 3 seconds, and 2B with asystole lasting for 3 seconds or more. The blood pressure falls before or simultaneously with the decrease in heart rhythm; and Type 3 (vasodepression), when the blood pressure decreases below 80 mmHg, and the heart rate is not lower than 10% of maximal value [4, 5].

## CASE REPORT

A 66-year-old woman was admitted to the Clinical Electrophysiology Department after in-flight syncope, which occurred during a flight from Warsaw to Naples in Italy. After the plane reached cruising altitude, the patient experienced vertigo and lost consciousness shortly after, remaining in sedentary position. A co-travelling doctor laid her down, confirmed the lack of breath and pulse, and immediately initiated basic life support procedures. After approximately 30 seconds the patient regained consciousness. She reported

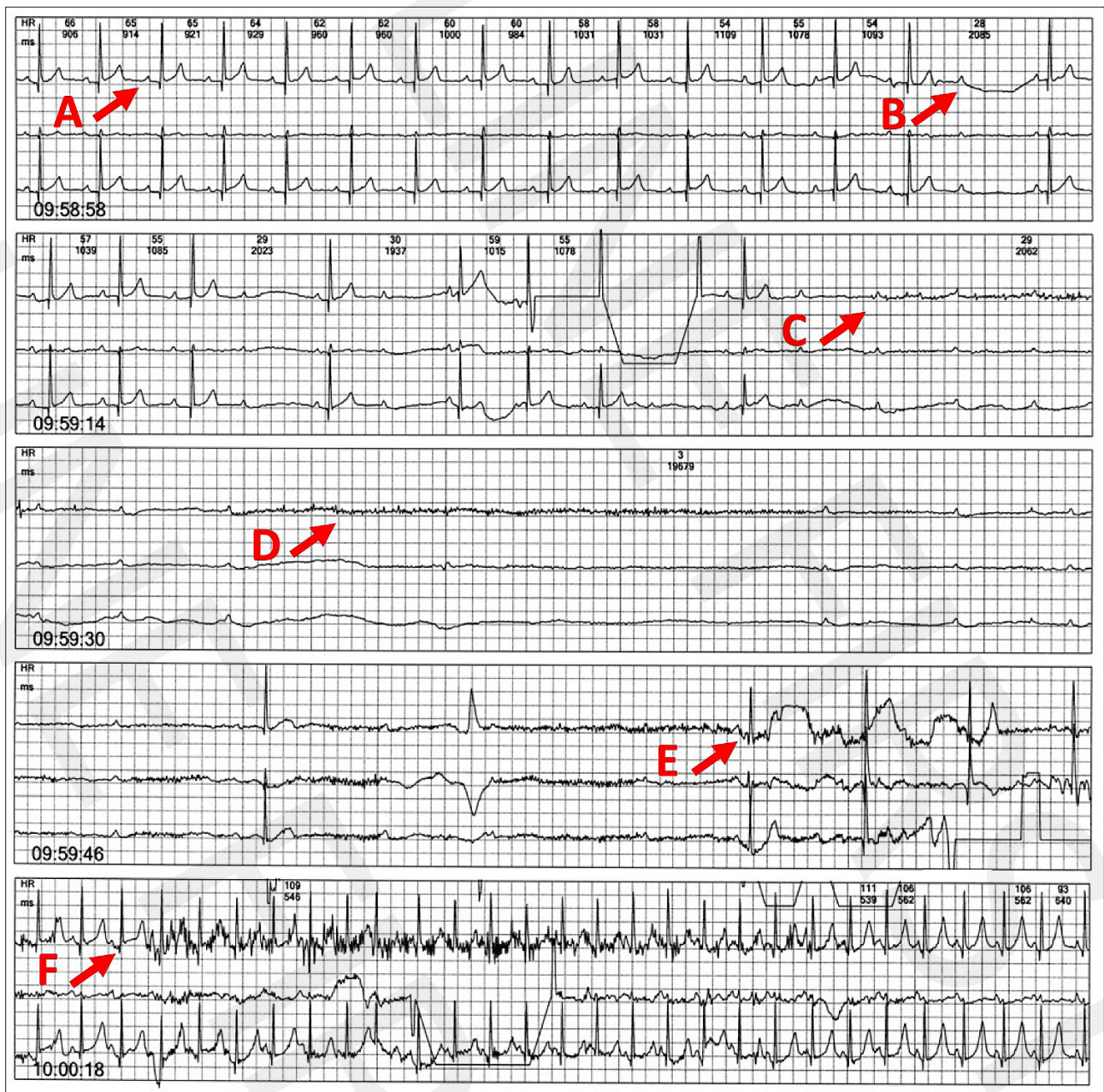
✉ Address for correspondence: Anna Wysocka, Department of Internal Medicine and Internal Nursing, Faculty of Health Sciences, Medical University, Lublin, Poland  
E-mail: annawysocka@umlub.pl

no alarming symptoms, and the flight continued. As she was afraid of flying again, she decided to return home by car.

The results of ambulatory diagnostics (ECG monitoring, echocardiography, and exercise test) were normal. The patient was referred for invasive electrophysiological study (EPS) which revealed normal parameters of atrial node and atrio-ventricular conduction, with neither arrhythmia induced during atrial and ventricular programmed stimulation in basic conditions, nor after isoproterenol administration. Considering the unexplained full-symptom syncope with no pulse detected, it was decided to extend the diagnostics with tilt-table testing according to the Westminster protocol. After 20 minutes in the vertical position, blood pressure decreased, the heart rate slowed down to 48 bpm (sinus bradycardia) with pre-synopal symptoms, and subsequent loss of consciousness. After tilting to the horizontal position, consciousness quickly

returned with normal heart rhythm and blood pressure. The test was considered positive and the patient was released from the tilt-table with Holter monitoring still active.

Shortly afterwards, in the sedentary position, patient reported the return of pre-synopal symptoms, the loss of consciousness, with seizures occurring. She regained consciousness as soon as she was laid down on the floor. In the ECG monitoring recorded at the time symptoms occurred, 20 second asystole due to complete atrioventricular (AV) block combined with transient sinus bradycardia (Fig.1). The cardio-depressive type of vaso-vagal syndrome was diagnosed. Considering the symptoms, it was decided to implant the patient with permanent dual-chamber pacemaker. On the next day, the implantation procedure was performed uneventfully, and since the 11-month follow-up the patient remains free of symptoms.



**Figure 1.** Holter-recorded 20-second asystole during delayed syncope in sedentary position following tilt-table test: A – normal sinus rhythm; B – 2:1 AV block; C – complete AV block; D – complete AV block combined with sinus bradycardia/asystole; E – sinus bradycardia with 1:1 AV conduction restored; F – post-synopal sinus tachycardia with normal AV conduction

## DISCUSSION

As previously reported, syncope – apart from being the cause of 25% of all emergencies in the air – accounts for 91% of new medical problems occurring on board an aircraft [1, 2, 6]. Several environmental factors involving atmospheric pressure fluctuations at altitude trigger disturbances in the cardiovascular system [7, 8]. During commercial aircraft flights, the majority of travellers are exposed to lower than usual atmospheric pressure conditions during which it is required that the pressure in aircraft cabins routinely should not be less than 574 mmHg. This is equivalent to atmospheric pressure at the altitude of 8,000 ft or 2,438 m. In conditions of acute altitude exposure, the pressure of arterial oxygen decreases. The tolerance of ambient hypobaric hypoxia prevailing in aircraft cabins at the cruising altitude is individual. In most patients, as a physiological compensation of hypoxia, alveolar minute ventilation increases, which results in lower carbon dioxide partial pressure and, subsequently, in ventilation inhibition. Vasodilatation, triggered by increasing hypobaric hypoxia, leads to reflex tachycardia and carotid baroreceptors stimulation. The enhanced sympathetic activity in healthy individuals is balanced by parasympathetic activation, yet in patients with disturbed parasympathetic response, the Bezold-Jarish reflex leads to significant bradycardia, hypotension and, finally, syncope. Patients with co-existing autonomic dysfunction, as a consequence of the stasis of venous blood in legs and subsequently reduced cerebral blood supply, most commonly experience in-flight syncope in the mechanism of orthostatic vasovagal hypotension [6, 8–10].

The majority of patients who experienced syncope during a flight, transiently lost consciousness when they stood up after prolonged sitting [8]. Nevertheless, VVS symptoms have also been reported in prolonged sedentary position in vehicle drivers [11, 12] or pilots [13, 14], with a possible risk of motor vehicle accidents or consequences for flight safety. The role of TTT for the diagnosis of unexplained syncope in of air crew members has been additionally mentioned [13, 14].

In the treatment of VVS, lifestyle modifications, such as good hydration, avoiding syncope-inducing situations, cautiousness with hypotensive or heart rate reducing medications, are essential. Additionally, physical counter-pressure manoeuvres such as leg crossing, arm gripping, and tilt training may also be effective in the significant improvement of symptoms. In patients with persistent symptoms, mineralocorticoid fludrocortisone or  $\alpha$ -adrenoreceptor agonist midodrine should be considered [15]. Finally, in the particular group of patients above 40-years-old with recurrent syncope and asystole, documented during tilt-test, implantation of dual-chamber pacemaker is indicated to prevent symptoms [16]. In patients qualified to permanent pacemaker implantation, available data suggest a favourable impact of an extraordinary approach for managing recurrent cardioinhibitory vasovagal syncope [17, 18].

Closed-loop stimulation (CLS) algorithm in dual chamber pacemakers, which allows for measurement of intracardiac impedance to assess right ventricular contractility and adjusts the pacing rate to prevent VVS, is seen as a promising treatment for patients with frequent or debilitating VVS, especially when medical therapy fails. Pacing mode 'DDD-CLS' should be used, with specific rate settings and CLS response adjusted to high or very high. However, in older patients, pacing efficacy may decline as VVS becomes more

vasodepressive rather than cardioinhibitory with age [19].

Another, relatively new method in managing with VVS is cardioneuroablation (CNA), during which cardiac ganglionated plexi are ablated to reduce excessive vagal activity. It was shown that this significantly reduces the recurrence of VVS (8% in the CNA group vs 54% in the control group) and improves quality of life [20]. The CNA is considered as promising intervention in patients with cardioinhibitory or mixed type of VVS, but further research and validation through larger studies is needed to refine patient selection, ablation targets, and long-term outcomes [21].

## CONCLUSIONS

- 1) Although vaso-vagal syndrome typically occurs in the vertical position, symptoms may also appear in a prolonged sedentary position.
- 2) Environmental factors, such as atmospheric pressure fluctuations at high altitude, may induce vaso-vagal syncope.
- 3) The Tilt-table test is a simple, safe, and useful tool for diagnosis of vaso-vagal syndrome.
- 4) Implantation of a 2-chamber pacemaker is the established method of treatment in patients over 40 years of age with recurrent syncope and asystole confirmed in the Tilt-table test.

## REFERENCES

1. Martin-Gill C, Doyle TJ, Yealy DM. In-Flight Medical Emergencies: A Review. *JAMA*. 2018;320:2580–2590. doi:10.1001/jama.2018.19842; PMID: 30575886
2. Borges do Nascimento IJ, Jerončić A, Arantes AJR, et al. The global incidence of in-flight medical emergencies: A systematic review and meta-analysis of approximately 1.5 billion airline passengers. *Am J Emerg Med*. 2021;48:156–164. doi:10.1016/j.ajem.2021.04.010
3. Jardine DL, Wieling W, Brignole M, et al. The pathophysiology of the vasovagal response. *Heart Rhythm*. 2018;15:921–929. doi:10.1016/j.hrthm.2017.12.013; PMID: 29246828; PMCID: PMC5984661
4. Cheshire WP Jr, Goldstein DS. Autonomic uprising: the tilt table test in autonomic medicine. *Clin Auton Res*. 2019;29:215–230. doi:10.1007/s10286-019-00598-9; PMID: 30838497; PMCID: PMC8897774
5. Brignole M, Menozzi C, Del Rosso A, Costa S, Gaggioli G, Bottoni N, et al. New classification of haemodynamics of vasovagal syncope: beyond the VASIS classification. Analysis of the pre-syncope phase of the tilt test without and with nitroglycerin challenge. *Vasovagal Syncope International Study*. *Eurpace*. 2000;2(1):66–76. doi:10.1053/eupc.1999.0064; PMID: 11225598
6. Kingsley T, Kirchoff R, Newman JS, et al. Demystifying airline syncope. *World J Cardiol*. 2020;12:107–109. doi:10.4330/wjc.v12.i3.107; PMID: 32280429; PMCID: PMC7138867
7. Błaszczyk RT, Gorlo A, Dukacz M, et al. Association between exposure to air pollution and incidence of atrial fibrillation. *Ann Agric Environ Med*. 2023;30:15–21. doi:10.26444/aaem/157189; PMID: 36999851
8. Seccombe LM, Peters MJ. Physiology in medicine: acute altitude exposure in patients with pulmonary and cardiovascular disease. *J Appl Physiol*. (1985). 2014;116(5):478–85. doi:10.1152/jappphysiol.01013.2013
9. Furián M, Tannheimer M, Burtcher M. Effects of Acute Exposure and Acclimatization to High-Altitude on Oxygen Saturation and Related Cardiorespiratory Fitness in Health and Disease. *J Clin Med*. 2022;11:6699. doi:10.3390/jcm11226699; PMID: 36431176; PMCID: PMC9697047
10. Chandra A, Conry S. In-flight Medical Emergencies. *West J Emerg Med*. 2013;14:499–504. doi:10.5811/westjem.2013.4.16052; PMID: 24106549; PMCID: PMC3789915
11. Corvino AR, Russo V, Monaco MGL, et al. Vasovagal Syncope at Work: A Narrative Review for an Occupational Management Proposal.

- Int J Environ Res Public Health. 2023;20(8):5460. doi:10.3390/ijerph20085460; PMID: 37107742; PMCID: PMC10138125
12. Chee JN, Simpson C, Sheldon RS, et al. A Systematic Review of the Risk of Motor Vehicle Collision in Patients With Syncope. *Can J Cardiol.* 2021;37:151–161. doi:10.1016/j.cjca.2020.02.070; PMID: 32504546
  13. Chiang KT, Yang CS, Chiou WY, et al. Repeated hypoxic syncope in a helicopter pilot at a simulated altitude of 18,000 feet. *Aviat Space Environ Med.* 2012;83:609–13. doi:10.3357/asem.3273.2012; PMID: 22764617
  14. Manen O, Perrier E, Généro M. Ground vasovagal presyncope and fighter pilot fitness: aeromedical concerns. *Aviat Space Environ Med.* 2011;82(9):917–20. doi:10.3357/asem.2620.2011; PMID: 21888279
  15. Brignole M, Moya A, de Lange FJ, et al. 2018 ESC Guidelines for the diagnosis and management of syncope. *Eur Heart J.* 2018;39:1883–1948. <https://doi.org/10.1093/eurheartj/ehy037>
  16. Glikson M, Nielsen JC, Kronborg MB, et al. ESC Scientific Document Group. 2021 ESC Guidelines on cardiac pacing and cardiac resynchronization therapy. *Eur Heart J.* 2021;42(35):3427–3520. doi:10.1093/eurheartj/ehab364
  17. Barón-Esquivias G, Barón-Solis C, Ordóñez A. Pacing for patients suffering from cardioinhibitory vasovagal syncope using the closed-loop system. *Front Cardiovasc Med.* 2020;6:192. doi:10.3389/fcvm.2019.00192; PMID: 32118042; PMCID: PMC7033422
  18. Akella K, Olshansky B, Lakkireddy D, Gopinathannair R. Pacing Therapies for Vasovagal Syncope. *J Atr Fibrillation.* 2020;13:2406. doi:10.4022/jafib.2406; PMID: 33024506; PMCID: PMC7533132
  19. van Dijk JG, van Rossum IA, van Houwelingen M, et al. Influence of Age on Magnitude and Timing of Vasodepression and Cardioinhibition in Tilt-Induced Vasovagal Syncope. *JACC Clin Electrophysiol.* 2022;8(8):997–1009. doi:10.1016/j.jacep.2022.05.009; Epub 2022 Jul 27; PMID: 35981805
  20. Piotrowski R, Baran J, Sikorska A, et al. Cardioneuroablation for Reflex Syncope: Efficacy and Effects on Autonomic Cardiac Regulation-A Prospective Randomized Trial. *JACC Clin Electrophysiol.* 2023;9:85–95. doi:10.1016/j.jacep.2022.08.011; pub 2022 Aug 28; PMID: 36114133
  21. Li L, Po S, Yao Y. Cardioneuroablation for treating vasovagal syncope: current status and future directions. *Arrhythm Electrophysiol Rev.* 2023;12:e18. doi:10.15420/aer.2023.02; PMID: 37457436; PMCID: PMC10345939