



How 5-ALA enlightens neurosurgery – results of a single centre study on high-grade gliomas

Marek Mazurek^{1,A-E}, Natalia Lehman^{1,B-E}, Filip Stoma^{1,C}, Gabriela Czaja^{1,B}, Agata Banach^{1,B}, Bożena Jarosz^{1,E}, Radosław Rola^{1,A,C,E-F}

¹ Department of Neurosurgery and Paediatric Neurosurgery, Medical University, Lublin, Poland

A – Research concept and design, B – Collection and/or assembly of data, C – Data analysis and interpretation, D – Writing the article, E – Critical revision of the article, F – Final approval of the article

Mazurek M, Lehman N, Stoma F, Czaja G, Banach A, Jarosz B, Rola R. How 5-ALA enlightens neurosurgery – results of a single centre study on high-grade gliomas. *Ann Agric Environ Med*. doi: 10.26444/aaem/194075

Abstract

Introduction and Objective. This study aims to assess the effectiveness of the use of intraoperative fluorescence with 5-ALA on the scope on the resection and the results of the treatment of patients. Despite the continuous development of new oncological treatments, surgical resection remains the basis for treating high-grade gliomas. For this reason, methods are introduced to facilitate the removal of the tumour in a maximally complete and safe manner for the patient.

Materials and Method. The effects were examined of intraoperative fluorescence using 5-aminolevulinic acid (5-ALA). The volumetric extent of resection and the outcome of 39 cases of patients with high-grade gliomas operated on using intraoperative fluorescence were compared with 5-ALA and patients undergoing resection using a white-light microscope.

Results. The use of 5-ALA during the procedure increased the extent of resection compared to procedures under white light: – 96.14% vs. 90.69%. Interestingly, when focused on recurrent high-grade gliomas, better results were observed for the white-light group. There was also an improvement in the overall survival (OS) of patients operated on with 5-ALA ($p=0.0485$). OS for the study group was 9.97 months compared to 6.40 months for the control group.

Conclusions. Based on the observations, the use of 5-ALA in surgery for high-grade gliomas allows for an increase in the extent of resection performed and an improvement in patient prognosis. Moreover, the use of 5-ALA shows better results for primary tumours when compared to recurrent ones ($p<0.0001$ for primary gliomas).

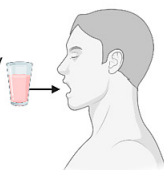Key words

Glioblastoma, Glioma, 5-ALA, Glioma treatment, fluorescence-guided surgery

5-ALA fluorescence guided resection of High Grade Glioma

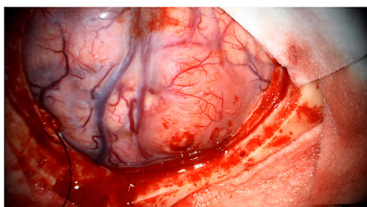
1 5-ALA administration

~3 hours prior surgery
20 mg/kg of body weight



Study group:
22 patients

Control group:
17 patients



5-aminolevulinic acid

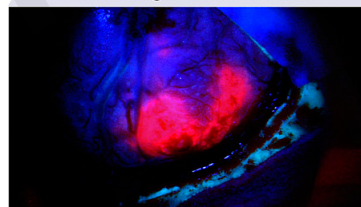
Tumor intracellular synthesis

Protoporphyrin IX

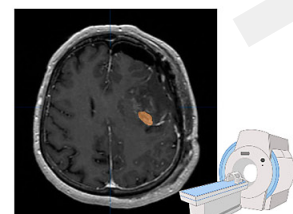
2 Fluorescence navigated surgery

Department of Neurosurgery and Paediatric Neurosurgery of the Medical University of Lublin, Poland

Blue-violet light with a wavelength of 375-440nm



3 Outcomes



5 months post surgery follow-up MRI

The use of 5-ALA during HGG resection is associated with a non-significantly longer operative time.

Achieving greater extents of resections.
96.14% vs 90.69% [medians]

Better resection results were observed for primary high grade glioma.

Surgeries with the use of 5-ALA result in significantly longer survival of patients ($p=0.0485$)

✉ Address for correspondence: Natalia Lehman, Department of Neurosurgery and Paediatric Neurosurgery, Medical University, Poland
E-mail: lehmannatalia8@gmail.com

Received: 01.03.2024; accepted: 03.10.2024; first published: 15.10.2024

INTRODUCTION

Despite the continuous development of medicine, there are diseases for which the treatment results have only slightly improved over the years. These include high-grade glioma (HGG) (WHO grade 3 and 4 gliomas), which are one of the most common tumours of the central nervous system [1]. Despite the implementation of standard forms of treatment, including surgical resection with radio and chemotherapy, the average overall survival time is approximately 15 months for glioblastoma (GBM) [2]. In recent years, significant hope for GBM patients has been placed on immunotherapies, including immune checkpoint inhibitors such as Nivolumab, a PD-1 blocking antibody, and Urelumab, an anti-LAG-3 antibody (NCT03493932, NCT02658981, respectively). Additionally, strategies aimed at reducing the functionality of immunosuppressive cells, among others myeloid-derived suppressor cells and FoxP3-positive regulatory T cells, are being explored. The highly suppressive tumour microenvironment is recognized as a major obstacle to translating promising results from murine studies into clinical trials [2].

Regardless of the numerous scientific projects on potential therapies for GBM, surgical resection of the tumour remains a crucial element in treatment and is key to patient survival. As shown in the literature, one of the important parameters, next to the age and Karnofsky index influencing the effectiveness of the therapy is the extent of the resection (EOR). However, due to the high tendency of tumour cells to migrate, achieving gross total resection (GTR; defined as at least 90%), as well as complete resection (defined by most authors as the removal of the entire tumour volume enhancing after the administration of contrast agents) is very difficult. The performed analyses showed the presence of tumour cells up to 4 cm from macroscopically visible tumour margins. Moreover, due to the high risk of post-operative neurological deficits resulting from damage to healthy brain tissue, the correct identification of neoplastic tissue during surgery is essential. For this purpose, several techniques have been developed to help the surgeon, for example, intraoperative magnetic resonance imaging (i-MRI), intraoperative computed tomography contrast-enhanced ultrasound, as well as intraoperative fluorescence [3].

The latter method consists of supplying the patient's body with a special photosensitizer that will allow visualization of the tumour tissue during the procedure owing to the light energy emitted under the influence of ultraviolet light. Many substances were used as photosensitizers, e.g. fluorescein, indocyanine green or 5-aminolevulinic acid (5-ALA). In the patient's body, 5-ALA undergoes a series of transformations, converting from a non-fluorescent substrate to protoporphyrin IX (PpIX), capable of emitting fluorescence. The emission of light by PpIX molecules occurs under specific conditions. To manage this, they must be illuminated with light with a wavelength of 375–440 nm. This necessitates the use of a special operative microscope equipped with an appropriate light source and a set of dedicated filters. As a result, tumour cells emit visible fluorescence in the form of red light with a wavelength in the range of about 635–704 nm [4].

Promising results of research on the effectiveness of the discussed method resulted in the acceptance of the use of 5-ALA in the treatment of HGGs by the European Medicine Agency in 2007, and the U.S. Food and Drug Administration in 2017 [5].

The study assesses the effectiveness of the use of intraoperative fluorescence with 5-ALA on the scope of the resection and the results of the treatment of patients, taking into considering such additional determinants as the genetic profile of the tumour cells and pharmacological factors.

MATERIALS AND METHOD

The study included patients diagnosed with high-grade glioma and admitted for tumour surgery at the Department of Neurosurgery and Paediatric Neurosurgery of the Medical University of Lublin, Poland, from May 2020 – November 2023. The study group consisted of 22 patients whose resection was aided by intraoperative fluorescence using 5-aminolevulinic acid (Gliolan®, Medac, Germany). The control group (CG) consisted of 17 patients diagnosed with HGG according to the WHO CNS5 2021 classification. They were selected retrospectively, for whom the surgery was performed before the 5-ALA use was standard. Patient selection criteria for SG were as follows: the presence of HGG, age 18 – 80, location of the tumour allowing surgical removal of the lesion, and providing informed written consent to participate in the study. The exclusion criteria for both SG and CG included: pregnancy, heart pacemaker or defibrillator, presence of metal elements in the brain or skull (except clips), other life-threatening diseases, and hypersensitivity to 5-ALA or porphyrins. Regurgitation after the Gliolan administration also excluded the patient from the study.

Table 1. An essential characteristic of patients included in the study as control and study groups

Characteristics	HGG patients with 5-ALA navigation n=22	HGG patients without 5-ALA navigation n=17
Gender		
Female [n]	12	10
Male [n]	10	7
Age		
Median (IQR) ¹	62 (47.25–67.0)	60 (53.0–70.0)
Min [yr]	28	30
Max [yr]	78	76
Primary HGG [n]	14	13
Recurrent HGG [n]	8	4

HGG, High-Grade Glioma; 5-ALA, 5-aminolevulinic acid. ¹The lower (Q1) and upper (Q3) quartiles were determined

Study design. Three hours before the procedure, patients were administered an aqueous solution of the photosensitising agent (20mg/kg of body weight). Leica M530 OHX and Zeiss Kinevo 900 neurosurgical microscopes equipped with an ultraviolet 400nm fluorescent light source, and dedicated filters were used. Conversion to UV light was performed when the tumour borders were visually indistinguishable from healthy brain tissue under microscopic magnification (Fig. 1, Panel I). Resection was completed when no tumour tissue was detected in the white light and there was no evidence of fluorescence in ultraviolet light. All patients had pre-operative magnetic resonance imaging (MRI) scans to confirm the tumour's location before surgery. Additionally, an MRI of the head was performed within 48 hours after the resection to assess the tumour bed, and volumetric assessment of the possible remnants of the lesion. The following data

were analyzed: the EoR and pharmacological treatment in the peri-operative period, surgery and hospitalization time, progression-free survival of patient, as well as 6-month and 1-year survival. EoR was assessed in both the study and control groups (Fig. 1, Panel II).

In addition, pharmacotherapy in the form of anti-epileptic drugs and steroids taken by patients in the perioperative period (i.e. 7 days before surgical treatment) was analysed. In the case of Valproic acid, the dose was between 800–1,000 mg per day, while all patients receiving Levetiracetam were taking it at a dose of 1,000mg per day. The daily doses of steroids used varied from 4–12 mg per day of Dexamethasone

or its equivalent dose. Progression-free survival (PFS) was determined based on the absence of new contrast enhancement in follow-up MRI. Volumetric analysis was carried out using OsiriX® software. The results from the study were compared to data from the literature [6].

Statistics. Statistical analysis was performed with GraphPad Prism 8.2.1 (GraphPad Software, San Diego, CA, USA) and Statistica 13.3 (StatSoft, Tulsa, OK, USA). The non-Gaussian data distribution was determined by the D'Agostino-Pearson test, followed by U Mann-Whitney U test for comparison between the two groups. Results were

Table 2. Characteristics of location and histological diagnosis of tumours of specific patients

Patient	Age [yr]	Male (M)/Female (F)	Tumour localization	Histological classification	Primary/Recurrent
Patient 1	74	F	Right frontal and temporal lobe, right insula	Glioblastoma, IDH-wildtype	Primary
Patient 2	63	F	Right frontal lobe	Glioblastoma, IDH-wildtype	Primary
Patient 3	64	F	Right frontal lobe	Glioblastoma, IDH-wildtype	Primary
Patient 4	62	M	Left frontal lobe	Glioblastoma, IDH-wildtype	Recurrent
Patient 5	73	F	Right temporal lobe	Glioblastoma, IDH-wildtype	Recurrent
Patient 6	54	F	Right temporoparietal area	Glioblastoma, IDH-wildtype	Recurrent
Patient 7	64	F	Left frontal lobe	Glioblastoma, IDH-wildtype	Primary
Patient 8	57	M	Left temporal lobe	Glioblastoma, IDH-wildtype	Primary
Patient 9	31	F	Right frontal lobe	Glioblastoma, IDH-wildtype	Primary
Patient 10	29	M	Left frontal lobe	Glioblastoma, IDH-wildtype	Primary
Patient 11	50	M	Right parietooccipital area	Glioblastoma, IDH-wildtype	Recurrent
Patient 12	47	F	Right temporal lobe	Glioblastoma, IDH-wildtype	Recurrent
Patient 13	63	F	Deep structures of the right hemisphere	Glioblastoma, IDH-wildtype	Primary
Patient 14	39	M	Right frontoparietal area	Oligodendroglioma, IDH-mutant, G3	Recurrent
Patient 15	73	F	Left frontal lobe	Glioblastoma, IDH-wildtype	Primary
Patient 16	28	M	Right periventricular area	Astrocytoma, IDH-mutant, G4	Primary
Patient 17	68	M	Right temporal lobe	Glioblastoma, IDH-wildtype	Recurrent
Patient 18	78	M	Right occipital lobe	Glioblastoma, IDH-wildtype	Primary
Patient 19	48	M	Left temporoccipital area	Astrocytoma, IDH-mutant, G4	Primary
Patient 20	43	F	Right frontal lobe	Glioblastoma, IDH-wildtype	Primary
Patient 21	62	M	Left frontoparietal area	Glioblastoma, IDH-wildtype	Recurrent
Patient 22	70	F	Right frontal lobe and right insula	Glioblastoma, IDH-wildtype	Primary
Patient 23	48	F	Frontal lobe and right insula	Glioblastoma, IDH-wildtype	Recurrent
Patient 24	54	F	Right temporal lobe	Glioblastoma, IDH-wildtype	Primary
Patient 25	68	F	Right temporal lobe	Glioblastoma, IDH-wildtype	Primary
Patient 26	73	F	Right temporal lobe	Glioblastoma, IDH-wildtype	Primary
Patient 27	59	F	Right frontal lobe	Oligodendroglioma, IDH-mutant	Primary
Patient 28	36	M	Right frontotemporal area	Astrocytoma, IDH-mutant, G3	Primary
Patient 29	71	F	Left parietooccipital area	Glioblastoma, IDH-wildtype	Primary
Patient 30	70	F	Right temporal lobe	Glioblastoma, IDH-wildtype	Primary
Patient 31	65	M	Left temporal lobe	Glioblastoma, IDH-wildtype	Primary
Patient 32	30	M	Left frontotemporal area	Oligodendroglioma, IDH-mutant	Primary
Patient 33	60	M	Right parietal area	Glioblastoma, IDH-wildtype	Recurrent
Patient 34	53	M	Right frontal lobe	Glioblastoma, IDH-wildtype	Primary
Patient 35	73	F	Right frontoparietal area	Glioblastoma, IDH-wildtype	Primary
Patient 36	63	F	Left frontotemporal area	Glioblastoma, IDH-wildtype	Primary
Patient 37	76	M	Right parietal lobe	Glioblastoma, IDH-wildtype	Recurrent
Patient 38	43	F	Right frontal lobe	Astrocytoma, IDH-mutant, G3	Primary
Patient 39	60	F	Left parietooccipital area	Glioblastoma, IDH-wildtype	Recurrent

HGG, High Grade Glioma; 5-ALA, 5-aminolevulinic acid; GBM, Glioblastoma multiforme; F, Female; M, Male

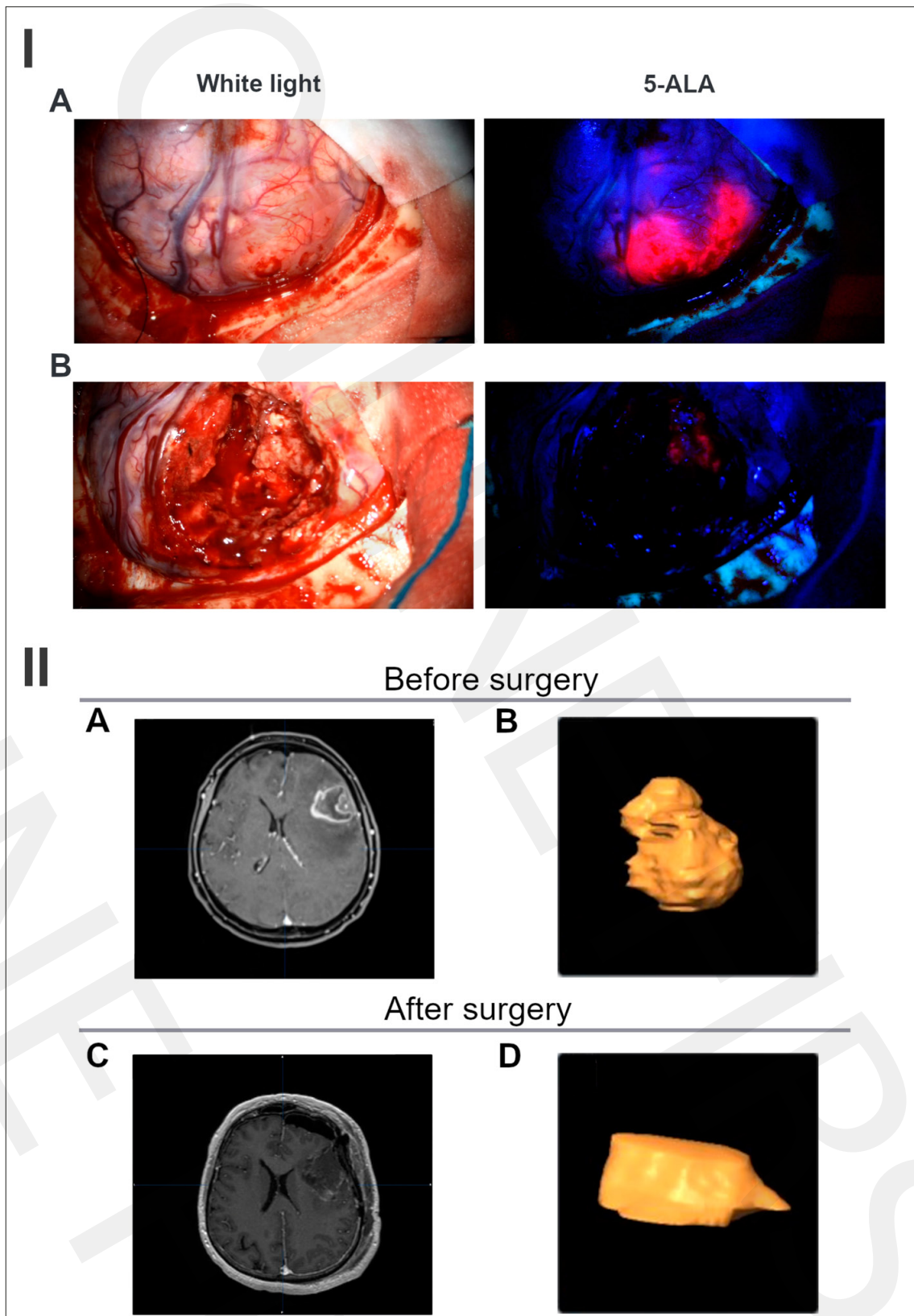


Figure 1. Panel I – fluorescence Imaging-assisted glioblastoma resection with 5-ALA presented in Intraoperative view under normal light conditions and PpIX fluorescence with BLUE 400 filter (Zeiss Kinevo 900). A – initial stage of resection; B – view of the resection cavity. Panel II – pre- and post-operative MRI of a patient harbouring a glioblastoma. A – Pre-operative contrast-enhanced T1-weighted MRI. B – Pre-operative volumetric reconstruction of the tumour; C – Post-operative contrast-enhanced T1-weighted MRI; D – Post-operative volumetric reconstruction of the residual tumour.

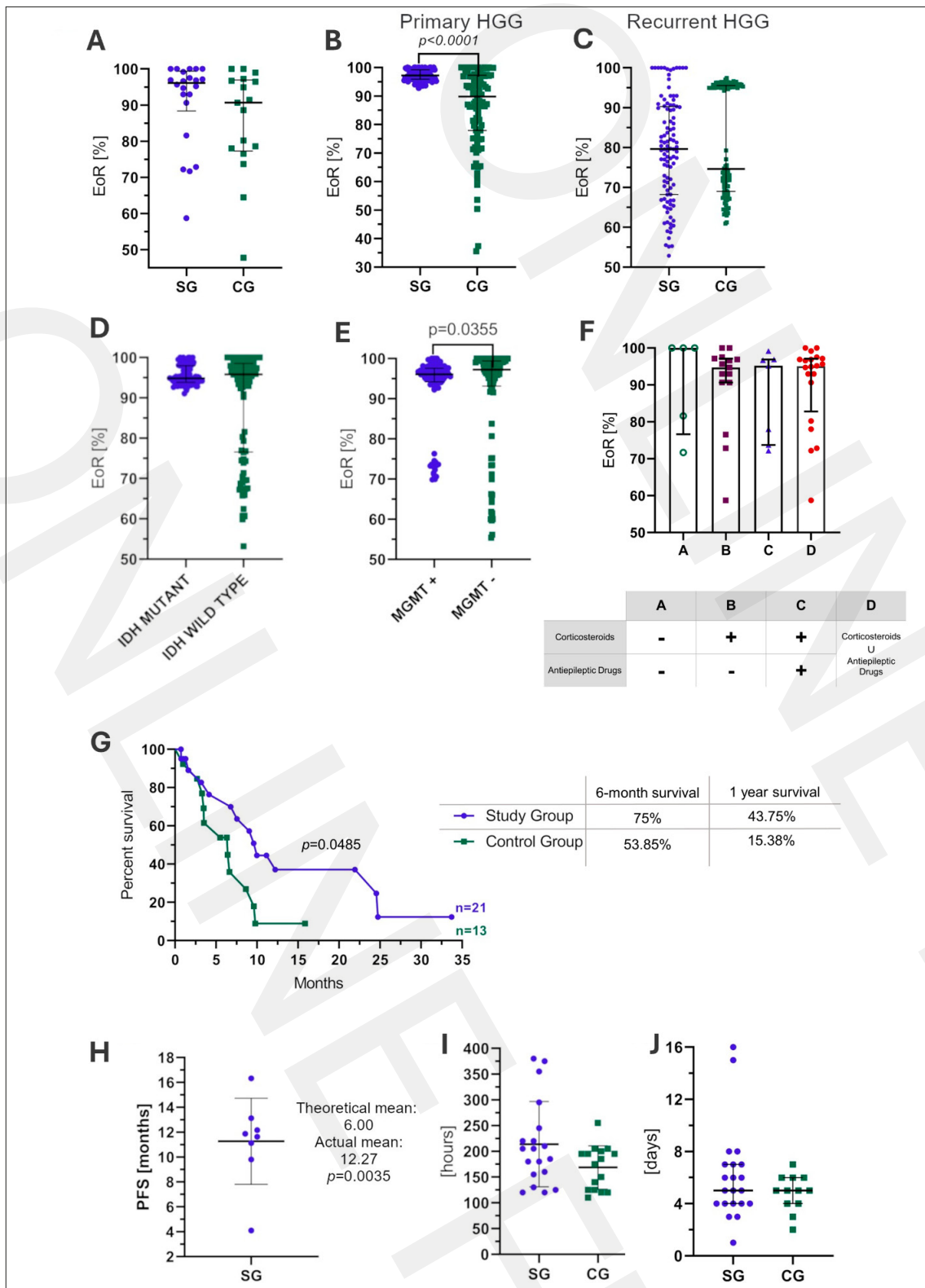


Figure 2. Extent of resection was analyzed between the study group and the control group (median 96.14% and 90.69%, respectively) (A). An additional EOR analysis for primary or recurrent tumour was taken into account (B and C), and showed a significantly improved extent of resection for primary gliomas ($p < 0.001$ for primary tumours). Additionally, the molecular profile of tumour, including IDH mutation and MGMT promoter methylation, was taken into consideration. Significantly better EORs were observed for patients with MGMT promoter methylation (D and E). As seen in Figure F, the impact of corticosteroids and anti-epileptic drugs was considered. Group A included patients who received neither steroid therapy nor antiepileptic treatment ($n = 5$). Group B consisted of patients who received only steroid therapy ($n = 15$). Further, group C contained patients who were taking both the corticosteroid and antiepileptic drugs ($n = 7$). Finally, group D included patients who had been treated with at least one of the above types of drugs ($n = 20$). Improved results were obtained for patients receiving neither corticosteroids nor anti-epileptic drugs. The improved 6-month and 1-year survival was observed for the 5-ALA group (G) (75% vs 43.75% and 53.85% vs 15.38%, respectively). The significances in overall survival were observed when comparing the study and control groups ($p < 0.05$). The mean of progression-free survival from our cohort (12.27 months) was contrasted with the mean from the control group of the Kim et. al study (6.00 months) [6]. EoR, Extent of resection; SG, Study Group; CG, Control Group; HGG, High-Grade Glioma; Union

presented as median and interquartile range. When the data met the normal distribution criteria, the unpaired t-test with mean and standard deviation was performed. Regarding the unrepresentative data for PFS of the control group, the one sample test for the study group was completed. As a hypothetical median, information from the SK Kim et. al article was used [6]. Due to the small group of patients for the primary vs secondary HGG comparison regarding the established percentage of resection, multiple probability simulation algorithms based on the Monte Carlo method were used. For the comparison between more than two groups, the Kruskal-Wallis test with Dunn correction was completed. Moreover, the survival, measured as time from the first surgery to death, was assessed with Kaplan-Meier curves along with the Long-rank test. The p -value of <0.05 was considered statistically significant.

RESULTS

More favourable resection ranges with the use of 5-ALA. In the 5-ALA group, the median EOR was 96.14%, while in the control group – 90.69% (Fig. 2A). When comparing primary and recurrent HGG (Fig. 2B,C), for the former, the EOR (end of range) was estimated at 97.24% for the study group and 89.85% for surgeries without the use of 5-ALA. Similarly, secondary HGG patients operated on with the use of 5-ALA were characterized by a greater EOR than patients operated on without this method (median 79.66% and 74.65%, respectively). It was also checked whether the molecular profile of the tumour affects the effectiveness of 5-ALA use. However, in the group of patients in the current study, the resection ranges depending on the presence of IDH (Isocitrate dehydrogenase) mutations or MGMT (O-6-methylguanine-DNA methyltransferase). Methylation did not show significant differences (Fig. 2D,E).

Corticosteroids and antiepileptic drug intake and additional analysed factors influencing the extent of resection. To analyze the effect of pharmacological treatment on the EOR with the use of 5-ALA, the study group was divided into 4 subgroups depending on the pharmacotherapy used in the peri-operative period (Fig. 2). The obtained results did not show significant differences in the EOR obtained in patients from groups B, C and D. However, in the case of patients not receiving either anti-epileptic treatment or steroid therapy, the median EOR was major for this group (100.00%), compared to the B, C, and D groups (94.71%, 95.19% and 95.07%, respectively). The data discussed in this section are summarized in Figure 2F.

Better prognosis for patients who had tumour resection performed with 5-ALA. The median survival time for patients whose surgery was performed with intra-operative fluorescence was 9.97 months (Fig. 2G). Moreover, 6-month and 1-year survival rates in this group of patients were 75% and 43.75%, respectively. On the contrary, analogous results for the control group were worse, as the median survival time was 6.4 months ($p < 0.05$ when compared SG to CG). Additionally, 53.85% and 15.38% of patients achieved 6-month and 1-year survival, correspondingly.

Figure 2H shows that the mean progression-free survival in the current study group was 11.27 months.

5-ALA and the course of treatment. The use of intra-operative fluorescence is associated with a longer procedure time, although the difference is not statistically significant. The dissimilarity of the medians for SG and CG was approximately 45 min. (Fig. 2I). The current analysis also included data on the time of hospitalization after the procedure. However, the results obtained did not reveal any differences between the 2 groups. In both cases the average hospital stay was 5 days (Fig. 2J).

DISCUSSION

One of the major objectives in glioma treatment is achieving a high EOR. The results of retrospective analysis by Lacroix et al. showed that removing 98% of the tumour volume extends the median survival from 8.8 to 13 months [7]. Suchorska et al., in their study analyzing the influence of EOR on the risk of neurological morbidity, suggested that the optimal EOR should be above 80%, as this is the value at which patient survival noticeably increases. Importantly, effective surgical treatment also affects the efficacy of adjuvant treatment, including both radiotherapy and chemotherapy [8].

As confirmed by data from the literature, the role of fluorescent dyes useful in glioma surgery can be successfully performed by several substances, which include, above all, indocyanine green, sodium-fluorescein and 5-aminolevulinic acid [4, 9].

The current study examined the impact of the 5-ALA which is currently used most commonly in the EOR. In patients operated on using fluorescence-guided intra-operative fluorescence, the average extent of resection was 96.14%. In the control group, where the surgery was performed under white light, this percentage was 90.69%. This indicates a significant increase in the volume of resected tumour tissue through the use of 5-ALA. Similar results were observed when considering only primary tumours or secondary tumours. In 2006, Stummer et al. published an analysis involving 270 cases of patients with high-grade malignant gliomas. Post-operative analysis showed that the use of 5-ALA allowed for a complete resection of the contrast-enhancing tumour in 65% of cases. The control group had a percentage of 36% [10]. Favourable values were obtained in a study by Kim et al. conducted on patients diagnosed with glioblastoma. The use of 5-ALA led to an increase in the average extent of resection from 84.7% under white light, to 97.0% using 5-ALA [11].

The use of intra-operative fluorescence allowed for an extension of the average lifespan of patients by 9.97 months, while in the control group, this indicator was only 6.4 months. Ng et al. described the treatment results of 74 patients with HGG. The use of 5-ALA extended the patients' survival from 8 months to 12 months, compared to the control group. Interestingly, this was also noted in cases without adjuvant therapy (8 months vs. 3 months) [12]. A greater discrepancy was shown in the work of Kim et al. The overall survival for patients operated on under white light was 14 months, while in the 5-ALA group, it was 24 months. Improvement was also evident in delaying disease recurrence. The progression-free survival (PFS) rate was 18 months in the research group, compared to only 6 months in the control group [6]. Prognostic analysis was also conducted in the above-mentioned study by Stummer et al. The patients

were divided into 2 age groups: >55 years and younger. For the first group, the use of 5-ALA extended the overall survival (OS) from 11.4 – 14.1 months, while for younger patients the increase was less pronounced. Furthermore, the 6 months without recurrence (PFS-6) was almost doubled (41.0% vs 21.1%) [13]. However, not all studies observed similar results. No improvement in OS was observed in the results of Picart et al. where PFS was significantly lower compared to the control group (7 months vs. 15 months) [14].

There are many potential reasons for such divergences in the available data in the literature. They can arise, among other things, from technical factors. The observation of fluorescence emitted by tumour tissue is performed with the 'naked eye', which lacks objective tools for assessing its intensity. As a result, its detection, and consequently the extent of resection, depends on the operator's experience and the conditions in the operating theatre. Another problem is the phenomenon of photobleaching. This involves a gradual decrease in the intensity of light generated by the fluorescent agent with prolonged exposure to activating light [15], which makes it difficult to detect tumour tissue during prolonged observation under UV light. However, in the case of resection surgeries, the use of a technique that gradually removes individual layers of the tumour tissue allows for minimizing this problem. While the cells located on the surface stop emitting visible fluorescence as the resection progresses, new layers of cells capable of emitting light are constantly uncovered. This requires the operator to use special techniques to detect the largest possible range of tumour tissue by revealing new layers of the tumour capable of emitting light energy [8]. Another reason may be the highly heterogeneous structure of the tumour tissue, which may affect the homogeneity of the emitted fluorescence.

Many authors emphasize the significance of the isocitrate dehydrogenase (IDH) status as one of the key markers of the malignancy grade of gliomas in contemporary medicine. The detection of mutations in the IDH1/2 gene has been associated with weaker fluorescence intensity [16]. This was also indirectly evident in patient group in the current study in which IDH wild-type tumour cases had a greater extent of resection achieved with 5-ALA, but the differences were not large (95.83% vs. 94.85%). However, even from this aspect, not all observations remain consistent [17]. The relationship between the quality of protoporphyrin IX (PpIX) fluorescence and the degree of malignancy has also been confirmed. The study by Jaber et al., in their sample of 166 tumours analyzed, showed that noticeable fluorescence was observed only in 16% (13/82) of low-grade gliomas, whereas the percentage was 85% (62/76) for more malignant tumours (WHO grade III) and 100% (8/8) for WHO grade IV tumours. In the same paper, the authors did not demonstrate any relationship between the intensity of luminescence and the methyguanine-DNA-methyltransferase (MGMT) methylation status [17]. This is consistent with the results obtained in our analysis.

Nowadays, a new widespread medical problem has emerged, which is the Severe Acute Respiratory Syndrome Coronavirus 2 (SARS-CoV2) infection. Although it is an infectious disease, it has had a significant impact on the treatment of patients with GBM, taking into account the logistical problems related to the safety of patients and staff, as well as additional complications of Coronavirus disease (COVID) resulting in improper functioning of the central nervous system (CNS). Contracting SARS-CoV-2 and

developing NeuroCOVID-19 can lead to various neurological effects, such as brain inflammation leading to such serious complications as cognitive impairments, psychosis, and strokes [18]. It alters the brain's environment and potentially affect the efficacy of treatments like 5-ALA. However, there is limited clinical research specifically examining the impact of NeuroCOVID-19 on the effectiveness of 5-ALA therapy in glioma patients. An *in vitro* study by Sakurai et al. demonstrated that 5-ALA treatment significantly inhibited SARS-CoV-2 infection in both healthy and cancerous cells. Additionally, cells with a more efficient 5-ALA metabolism showed prolonged resistance to SARS-CoV-2, with the anti-viral effect being dose-dependent [19]. This subject holds significant clinical importance and warrants further investigation.

In the current study, a difference was noted in the effectiveness of resection using 5-ALA between primary and secondary neoplasms. Recurrent tumours exhibit less regular growth patterns, which can result in a heterogeneous distribution of tumour cells within the tumour. In recent studies, Ricardi et al. analyzed the fluorescence status of primary and recurrent glioblastomas. The authors noted a higher percentage of emitted light unrelated to the presence of tumour cells in the case of recurrent lesions. The main causes of these observed reactions were inflammatory processes and signs of pseudo-progression [20]. This phenomenon can interfere with the accurate detection of the tumour border, leading to incomplete resection. Another aspect related to previous radiotherapy is the presence of radiation necrosis. It has been shown that within the necrotic tissue, there is a disturbance in the mechanisms of 5-ALA conversion (probably due to decreased UROS activity), leading to increased accumulation of uroporphyrinogen I [21].

One factor that can interfere with the effectiveness of 5-ALA, which is often neglected in the available literature, is pharmacotherapy used in the peri-operative period. Data available in the literature show that drugs administered to patients can affect both the accumulation of the fluorescent dye and its metabolism, thereby affecting the quality of fluorescence [4]. Therefore, the impact was analyzed of the most commonly used adjuvant treatments in patients with CNS tumours, such as steroids and anti-epileptic drugs (AEDs). For the study, patients were divided into 4 subgroups: those not receiving any adjunctive treatment, those receiving only cortico-steroids, those taking medications from both groups, and those receiving either steroids or AEDs. However, the conducted statistical analysis did not show a strong correlation between the extent of achieved resection in the last 3 groups. Similar results were observed in the study by Wadiura et al. in which the authors analyzed the treatment outcomes of 110 patients with gliomas using 5-aminolevulinic acid. After statistical analysis, no correlation was found between tumour fluorescence and the administered anti-epileptic treatment. The percentage of cases showing fluorescence was similar in all analyzed groups: patients not taking AEDs (29%), those taking levetiracetam LEV alone (43%), those taking LEV with another AED (45%), and those taking another AED (32%). It should be noted, however, that the above-mentioned study included patients not only with higher grade gliomas (HGG) but also with lower-grade gliomas (LGG) (WHO 2) [22].

The significance of steroid administration in 5-ALA-induced tumour fluorescence was also evident in the

observations of an *in vitro* study by Lawrence et al. The authors demonstrated that dexamethasone administration induced greater PpIX cell retention. This effect was not observed when steroids were used in combination with valproic acid, levetiracetam, or desmipramine, but it was also present when phenytoin was used. Some authors note that steroid administration may affect the integrity of the blood-brain barrier, leading to weaker penetration of 5-ALA into tumour cells [23]. There are also reports of a relationship between the administration of anti-epileptic drugs and the activity of enzymes involved in the metabolism of 5-ALA. However, translating this connection to the specific environment of malignant glioma cells requires further observation.

Based on the experience of the authors of the current study, another aspect is the increased complexity of the surgical procedure itself. First of all, UV-light conditions significantly limit visibility and hinder orientation in the surgical field, affecting the pace of work and the comfort of the operator. In practice, for optimal utilization of PpIX properties, multiple conversions between white and ultraviolet light are necessary during the surgery. Typically, tumour fluorescence is observed during lesion identification, after which it is removed in the most visible range under magnification with white light. In the final stage of the procedure, there is a re-conversion to ultraviolet light to remove any remaining tumour remnants that are not visible even to the 'naked eye' equipped with a microscope. Changes in lighting conditions affect the work of the remaining staff, as all light sources except those necessary for the procedure are turned-off in the operating theatre to minimize light contamination that interferes with the operator's fluorescence perception. All these factors can lead to prolonged procedure duration and might expose the patient to a higher risk of complications associated with anesthesia and the surgery itself. Additionally, it increases the workload and extends the working time of the entire staff, resulting in additional costs. In the control group, surgery time was significantly shorter compared to the procedures utilizing 5-ALA. Another aspect that may impact treatment costs is the duration of hospitalization after the surgery. The use of 5-ALA aims to increase the precision of resection and, consequently, minimize damage to healthy brain tissue. Likewise, in the observations of the authors, the hospitalization period did not differ between the control and experimental groups.

The topic of the cost-effectiveness of intra-operative fluorescence using 5-ALA has been addressed by many authors. In 2013, Slof et al. published the results of their analysis on the cost-effectiveness of intraoperative fluorescence using 5-ALA in standard clinical practice conditions in Spain. The authors calculated an additional cost of €4,550 necessary to achieve complete resection compared to standard surgery. The cost per additional quality-adjusted life year (QALY) was €9,021 per QALY gained [24]. A similar study is the analysis by Esteves et al. The authors used a Markov model (cohort simulation) to evaluate the cost-effectiveness of 5-ALA fluorescence-guided neurosurgery compared with white-light surgery in adult patients with newly-diagnosed high-grade glioma. They compared the treatment costs obtained from official Portuguese reimbursement lists (2012 values) with their results, including QALY, life-years, and progression-free life-years. Based on their findings, the authors confirmed the cost-effectiveness of the analyzed method compared to traditional white-light surgery [25].

CONCLUSIONS AND CLINICAL IMPLICATIONS

New methods of neuro-navigation, including the use of 5-ALA, need to be implemented to facilitate the removal of as many glioma cells as possible in a manner safe for the patient, which is the subject of this study. A limitation of the study is the relatively small number of patients. 5-ALA can be effectively used to increase the scope of resection of high-grade tumours. What is interesting in the study, is that the usage of 5-ALA achieves better results for primary tumours rather than recurrent ones. For patients in the study, the use of 5-ALA prolonged overall survival as well as delayed disease relapse. The results obtained are consistent with data available in the literature. At the same time, this successful method is minimally invasive, associated with a low incidence of adverse events, and is relatively simple to apply.

REFERENCES

- Legmouz M, Ouahabi AE, Boulbaroud S, Azzaoui FZ. BRAIN TUMOURS AMONG MOROCCAN ADOLESCENTS IN THE REGION OF RABAT-SALE-KENITRA, MOROCCO. *Acta Neuropsychol.* 2022;20(3):345–353. doi:10.5604/01.3001.0016.0760
- Obrador E, Moreno-Murciano P, Oriol-Caballo M, et al. Glioblastoma Therapy: Past, Present and Future. *International Journal of Molecular Sciences.* 2024;25(5):2529. doi:10.3390/ijms25052529
- Della Pepa GM, Ius T, La Rocca G, et al. 5-Aminolevulinic Acid and Contrast-Enhanced Ultrasound: The Combination of the Two Techniques to Optimize the Extent of Resection in Glioblastoma Surgery. *Neurosurgery.* 2020;86(6):E529–E540. doi:10.1093/neuros/nyaa037
- Mazurek M, Kulesza B, Stoma F, Osuchowski J, Mańdziuk S, Rola R. Characteristics of Fluorescent Intraoperative Dyes Helpful in Gross Total Resection of High-Grade Gliomas-A Systematic Review. *Diagnostics (Basel).* 2020;10(12):1100. doi:10.3390/diagnostics10121100
- Eatz TA, Eichberg DG, Lu VM, Di L, Komotar RJ, Ivan ME. Intraoperative 5-ALA fluorescence-guided resection of high-grade glioma leads to greater extent of resection with better outcomes: a systematic review. *J Neurooncol.* 2022;156(2):233–256. doi:10.1007/s11060-021-03901-9
- Kim SK, Choi SH, Kim YH, Park CK. Impact of fluorescence-guided surgery on the improvement of clinical outcomes in glioblastoma patients. *Neurooncol Pract.* 2014;1(3):81–85. doi:10.1093/nop/npu011
- Lacroix M, Abi-Said D, Fournier DR, et al. A multivariate analysis of 416 patients with glioblastoma multiforme: prognosis, extent of resection, and survival. *J Neurosurg.* 2001;95(2):190–198. doi:10.3171/jns.2001.95.2.0190
- Suchorska B, Weller M, Tabatabai G, et al. Complete resection of contrast-enhancing tumour volume is associated with improved survival in recurrent glioblastoma-results from the DIRECTOR trial. *Neuro Oncol.* 2016;18(4):549–556. doi:10.1093/neuonc/nov326
- Ahrens LC, Krabbenhoft MG, Hansen RW, et al. Effect of 5-Aminolevulinic Acid and Sodium Fluorescein on the Extent of Resection in High-Grade Gliomas and Brain Metastasis. *Cancers (Basel).* 2022;14(3):617. doi:10.3390/cancers14030617
- Stummer W, Novotny A, Stepp H, Goetz C, Bise K, Reulen HJ. Fluorescence-guided resection of glioblastoma multiforme by using 5-aminolevulinic acid-induced porphyrins: a prospective study in 52 consecutive patients. *J Neurosurg.* 2000;93(6):1003–1013. doi:10.3171/jns.2000.93.6.1003
- Kim S, Kim JE, Kim YH, et al. Glutaminase 2 expression is associated with regional heterogeneity of 5-aminolevulinic acid fluorescence in glioblastoma. *Sci Rep.* 2017;7(1):12221. doi:10.1038/s41598-017-12557-3
- Ng WP, Liew BS, Idris Z, Rosman AK. Fluorescence-Guided versus Conventional Surgical Resection of High Grade Glioma: A Single-Centre, 7-Year, Comparative Effectiveness Study. *Malays J Med Sci.* 2017;24(2):78–86. doi:10.21315/mjms2017.24.2.10
- Stummer W, Pichlmeier U, Meinel T, et al. Fluorescence-guided surgery with 5-aminolevulinic acid for resection of malignant glioma: a randomised controlled multicentre phase III trial. *Lancet Oncol.* 2006;7(5):392–401. doi:10.1016/S1470-2045(06)70665-9

14. Picart T, Armoiry X, Berthiller J, et al. Is fluorescence-guided surgery with 5-ala in eloquent areas for malignant gliomas a reasonable and useful technique? *Neurochirurgie*. 2017;63(3):189–196. doi:10.1016/j.neuchi.2016.12.005
15. Belykh E, Miller EJ, Patel AA, et al. Optical Characterization of Neurosurgical Operating Microscopes: Quantitative Fluorescence and Assessment of PpIX Photobleaching. *Sci Rep*. 2018;8(1):12543. doi:10.1038/s41598-018-30247-6
16. Ohba S, Murayama K, Kuwahara K, et al. The Correlation of Fluorescence of Protoporphyrinogen IX and Status of Isocitrate Dehydrogenase in Gliomas. *Neurosurgery*. 2020;87(2):408–417. doi:10.1093/neuros/nyz524
17. Jaber M, Wölfer J, Ewelt C, et al. The Value of 5-Aminolevulinic Acid in Low-grade Gliomas and High-grade Gliomas Lacking Glioblastoma Imaging Features: An Analysis Based on Fluorescence, Magnetic Resonance Imaging, 18F-Fluoroethyl Tyrosine Positron Emission Tomography, and Tumour Molecular Factors. *Neurosurgery*. 2016;78(3):401–411. doi:10.1227/NEU.0000000000001020
18. Akin LB, Neve JED, Dunn EW, et al. THE NEUROLOGICAL CONSEQUENCES OF CONTRACTING COVID-19. *Acta Neuropsychologica*. 2021;19(3):301–305. doi:10.5604/01.3001.0014.9953
19. Sakurai Y, Ngwe Tun MM, Kurosaki Y, et al. 5-amino levulinic acid inhibits SARS-CoV-2 infection in vitro. *Biochem Biophys Res Commun*. 2021;545:203–207. doi:10.1016/j.bbrc.2021.01.091
20. Ricciardi L, Sturiale CL, Scerrati A, et al. 5-Aminolevulinic Acid False-Positive Rates in Newly Diagnosed and Recurrent Glioblastoma: Do Pseudoprogession and Radionecrosis Play a Role? A Meta-Analysis. *Front Oncol*. 2022;12:848036. doi:10.3389/fonc.2022.848036
21. Beika M, Harada Y, Minamikawa T, et al. Accumulation of Uroporphyrin I in Necrotic Tissues of Squamous Cell Carcinoma after Administration of 5-Aminolevulinic Acid. *Int J Mol Sci*. 2021;22(18):10121. doi:10.3390/ijms221810121
22. Wadiura LL, Mischkulnig M, Hosmann A, et al. Influence of Corticosteroids and Antiepileptic Drugs on Visible 5-Aminolevulinic Acid Fluorescence in a Series of Initially Suspected Low-Grade Gliomas Including World Health Organization Grade II, III, and IV Gliomas. *World Neurosurg*. 2020;137:e437–e446. doi:10.1016/j.wneu.2020.01.243
23. Teng L, Nakada M, Zhao SG, et al. Silencing of ferrochelatase enhances 5-aminolevulinic acid-based fluorescence and photodynamic therapy efficacy. *Br J Cancer*. 2011;104(5):798–807. doi:10.1038/bjc.2011.12
24. Slof J, Diez Valle R, Galván J. Cost-effectiveness of 5-aminolevulinic acid-induced fluorescence in malignant glioma surgery. *Neurologia*. 2015;30(3):163–168. doi:10.1016/j.nrl.2013.11.002
25. Esteves S, Alves M, Castel-Branco M, Stummer W. A pilot cost-effectiveness analysis of treatments in newly diagnosed high-grade gliomas: the example of 5-aminolevulinic Acid compared with white-light surgery. *Neurosurgery*. 2015;76(5):552–562; discussion 562. doi:10.1227/NEU.0000000000000673